

Case Report

Wireless Spinal Cord Stimulation for the Treatment of Low Back and Bilateral Leg Pain after Ladder Surgery of Scoliosis and Spine Collapse

Pawan Grover¹, Alaa Abd-Elseyed², Niek Vanquathem^{3*}

¹Houston Surgery Center, Stimwave Technologies, USA

²Wisconsin School of Medicine and Public Health, USA

³Vice President of Clinical Affairs, Stimwave Technologies, USA

*Corresponding author: Niek Vanquathem, Vice President of Clinical Affairs, Stimwave Technologies, USA

Citation: Grover P, Abd-Elseyed A, Vanquathem N (2019) Wireless Spinal Cord Stimulation for the Treatment of Low Back and Bilateral Leg Pain after Ladder Surgery of Scoliosis and Spine Collapse. Chron Pain Manag 3: 119. DOI: 10.29011/2576-957X.100019

Received Date: 11 December, 2019; **Accepted Date:** 18 December, 2019; **Published Date:** 24 December, 2019

Abstract

Background: Failed Back Surgery Syndrome (FBSS) is a common, complex painful condition, especially difficult to treat in the elderly patients who present with multiple co-morbid factors. Neuromodulation can be an effective modality in the management of chronic pain in these patients. However, conventional spinal cord stimulation (SCS) systems are reported to have multiple adverse events and failures.

Case Illustration: A 67-year-old male patient was diagnosed with chronic pain syndrome, displacement of a lumbar intervertebral disc, and radiculopathy of the lumbar region. He presented with bulging discs in the T12 to L3 region, and spondylotic ridging from C3 to C5 and L3 to S1. He had undergone spinal fixation with transpedicular screws, intervertebral cage grafts, multiple laminectomies and correcting ladder surgery, creating a structure between the pelvis and spine to provide stabilization because of scoliosis and danger of spinal collapse. Despite the multiple interventions, he continued to have low back and bilateral leg pain down to the feet, and numbness with loss of function.

Objective: Demonstrate effectiveness of a minimally invasive wireless spinal cord stimulator in the treatment of chronic back and leg pain after spine surgery, in a patient with multiple co-morbidities.

Results: The subject had a satisfactory percutaneous trial and received a permanent implantation 2 weeks later. His pain scores (NRS) went down by 80% with reduced pain medication at all three follow-up dates (one, three and six months) compared to a mean pain score of 6/10 at rest and 9/10 with activity before the implant.

CONCLUSION: Wireless spinal cord stimulation (SCS) was successful for this 67-year-old suffering debilitating low back and leg pain due to multiple corrective back and neck surgery for scoliosis and spinal collapse. This technology is one of the least traumatic and effective options available and allows a variety of stimulation patterns for complicated cases.

Keywords: Wireless neurostimulation; Chronic back and leg pain; Scoliosis surgery; spine collapse

Introduction

Chronic pain may persist after anatomically successful spine surgery; a condition referred to as Post-Laminectomy Syndrome (PLS) or Failed Back Surgery Syndrome (FBSS). Over 300,000 spinal fusions are performed annually in the United States and it

has been reported that up to 40% of subjects continue with long term, post-procedural, chronic back pain [1]. Causes for FBSS have been reported to include epidural scarring, arachnoiditis, dural sac deformity and spinal instability [1].

It is very often seen in elderly patients that multiple medical co-morbidity or surgical aftermath contribute to back or leg pain; usually attributed to diabetic neuropathy, Peripheral Vascular Disease (PVD), or multiple bone pathologies. The distribution

of pain in these conditions can overlap the chronic pain in the extremities from FBSS, including back and buttock areas [2-4].

When alternative treatments such as physical therapy, pharmacological management or injection-based interventional pain therapies fail, SCS may provide a viable, implantable solution. SCS is a widely accepted treatment for chronic pain due to FBSS and Complex Regional Pain Syndrome (CRPS) [5,6]. However, conventional wired SCS systems are not without complications. Due to the bulk of the Implantable Pulse Generator (IPG) and the extensive wiring connecting the electrodes with the battery, the relative distance between the electrodes and spinal cord can change with bodily positions [7,8]. Conventional SCS has been reported to have a high rate of complications and adverse events, including implant-related complications such as battery failure, battery dislocations, disconnections of the electrodes from the battery, and IPG pocket pain.

Wireless neurostimulation (Stimwave, Pompano Beach, FL, USA) has been used effectively for the treatment of chronic pain of multiple aetiologies and reports have shown to long-term sustainable pain relief [9-11]. In patients with multiple co-morbidities, this minimally invasive, wireless system offers additional advantages, such as reduced procedural time, minimal surgical incisions, and reduced bulk of the implant.

Case Illustration

The patient is a 67-year old male, diagnosed with chronic pain syndrome, displacement of a lumbar intervertebral disc, and radiculopathy of the lumbar region. He presented with bulging discs in the T12 to L3 region, and spondylotic ridging from C3 to C5 and L3 to S1. He had undergone spinal fixation in 2012 with transpedicular screws transfixing the L2 to L5 vertebral bodies, intervertebral cage grafts at L2 to L4, and L4 to L5, and multiple laminectomies.

After an experimental “ladder surgery” to create a structure between the pelvis and spine to provide stabilization after the effects of scoliosis and danger of spinal collapse, the patient was told that he would likely never walk again, but he was nevertheless able to continue to walk with an assistive device after surgery. Despite these multiple surgeries, the patient continued to have low back and bilateral leg pain down to the feet. Particularly at night, he experienced extreme pain that prevented him from sleeping more than a few hours at a time. The patient also experienced numbness and loss of function. He lacked the ability to fully flex his feet at the ankle joint or to walk without catching his toes or tripping.

His medical history included hypertension, diabetes, arthritis, and hyperlipidaemia. He had a stroke in 1998, spinal fusion for scoliosis in 2006, radical prostatectomy in 2007, hand surgery in 2008, and a bladder/sphincter implant in 2009. He had surgeries for intestinal polyps, haemorrhoids, and ulcers in 2005. There was

history of seizures following tramadol administration in 2011. For his chronic low back pain, he underwent bilateral sciatic nerve blocks (2012), and bilateral sacroiliac joint block (2012), as well as epidural injections and physical therapy. He had been treated unsuccessfully with NSAIDs and oral opiates (Table 1).

Medication pre implant	Daily dose
Janumet	50-1000 mg, orally, twice a day
Crestor	10 mg
Aspirin	81 mg
Levemir	100 unit
Lisinopril	5 mg
Pre-implant Hydrocodone	5/500 mg, orally, each 6 hours
Epidural steroid injections	tried pre-implant

Table 1: Medications and doses.

At his initial visit, his pain score (NRS) was 6/10 average with medication, which increased to 10/10 with activity. The patient had failed all prior, less invasive interventional treatments as well as other invasive options and was no longer a candidate for further spinal surgery, since there were many anatomical changes to the spine and surrounding structures as a result of the past procedures. He had scar tissue, fusions limiting motion and hardware that limited options for entry to the epidural space. Since the patient did not want to pursue intrathecal pain pump therapy, wireless SCS was chosen. The system could be implanted with the least amount of structural trauma, recovery time and risk to the patient, but still offered the greatest variety of stimulation patterns to give him the best chance at finding pain reduction. The fact that this minimum invasive procedure could be done under light Monitored Anaesthesia Care (MAC) without a need for laminectomy or future surgical replacements were all key considerations in the device selection. A traditional system requiring general anaesthesia, paddle leads, a laminectomy and a large Implantable Power Generator (IPG) pocket with many battery replacement surgeries in years to come would not have been appropriate for this individual patient.

Device Description

An eight-contact wireless stimulator, which is 1.3 mm in diameter with an embedded microprocessor, was implanted through a Touhy needle at the anatomical midline between T9 and T10 vertebral levels. A thin receiver element was then coupled with the stimulator, tunneled and fixated subcutaneously. A small, external, rechargeable wireless pulse generator with attached transmitting antenna is worn by the patient over one layer of clothing to provide stimulation parameters and energy wirelessly to the implanted receiver, which then relays the wireless power

and signal to the stimulator electrodes. This device uses RF energy at a carrier frequency of 915 MHz to transfer the energy and signal and has a selection of therapeutic parameters as indicated for clinical use by the physician. This technology allows for a wide spectrum of stimulation parameters to be selected for clinical use, including: amplitudes from 1 to 24 mA, pulse widths from 10-1000 microseconds, and frequencies from 5 to 10,000 Hz.

Trial Procedure

The patient underwent a four-day neurostimulation trial with two, eight-contact temporary trial stimulators, exiting the body under a sterile bandage. A Tuohy needle under fluoroscopic guidance was used to reach the epidural space at T12/L1, the stylet was removed, and the trial leads were inserted through the needle cannula. The electrodes were positioned at mid body of T9 and top of T10 vertebral levels. Once the position of the electrode array was confirmed, the Tuohy needle was removed, and the steering stylet was replaced with the receiver stylet. The external portion of the trial stimulator was fixated to the skin. The system was programmed with a pulse rate of 60 Hz and pulse width of 340 ms at 4 mA, which was found to provide pain relief on the table. The pain reduction observed during the trial period was 0/10 with a reduction in medication as compared to a baseline score of 8/10 prior to the device placement, even while medicated. After four days, this trial stimulator was removed.

Permanent Implant Procedure

The permanent implant was done under MAC, 15 days after the trial with the temporary implant concluded. Two small stab wounds were made and a Tuohy needle was used to place each stimulator in the epidural space, entering at the T12/L1 space. The electrode arrays of the stimulators were staggered, spanning T8 to T11 vertebral bodies (Figure 1), and the two stimulators were positioned similarly as during the trial procedure. Receivers were placed into the inner lumen of both stimulators, and the stimulators were permanently anchored in place at the insertion site with the injectable, suture-less SandShark Injectable Anchor System, with one anchor per stimulator (Figure 2). The stimulators were subcutaneously tunnelled 12 cm distal from the entry point of the epidural space towards a separate receiver pocket. The distal portion of the receiver was coiled, sutured to itself and then fixated by running anchor stitches deep into the fascia, then through the tip of the distal receiver housing. The fascia and skin of the receiver pocket were closed in layers. There were no complications during the procedure or afterwards.

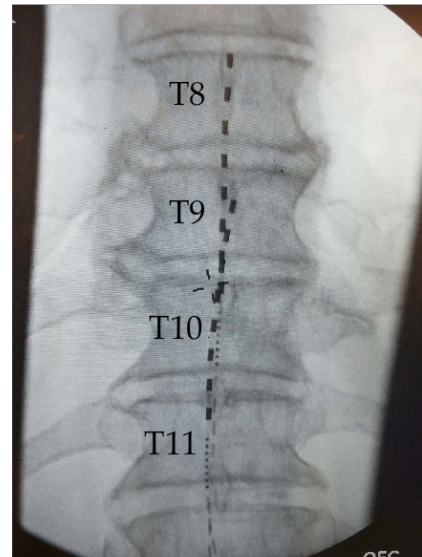


Figure 1: Image of AP Electrodes spanning T8-T11.

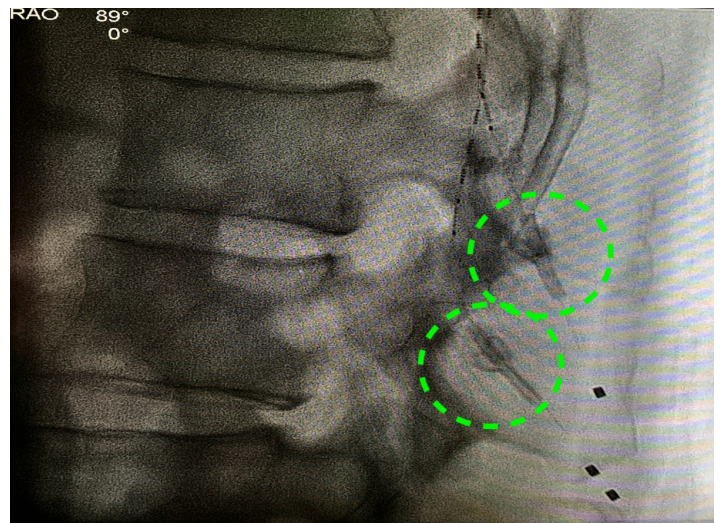


Figure 2: Suture-less SandShark Injectable Anchor System, with 1 anchor per stimulator.

Results

Data collection was done at one, three and six months after the permanent implant procedure. Pain scores according to the Numeric Rating Scale (NRS) were consistently down to 2/10 during each follow-up, while using less medication, reflecting an

80% reduction in pain compared to the baseline pain scores of 6/10 average at rest and 9/10 during activity. This improvement was also reflected in medication consumption: hydrocodone pre-implant was 5/500 mg each 6 hours and after implant hydrocodone was 10/325 mg as required, with the patient reporting that he rarely found a need for medication.

The patient also reported a measurable improvement in his quality of sleep. Prior to the wireless SCS, he noted 3 to 4 hours of poor quality sleep a night and was waking up frequently throughout the night due to pain. After the implant, the patient had uninterrupted sleep an average of 7 hours per night.

There was significant improvement in his ability to walk. He is now completely ambulatory without his assistive device. The patient reported that he no longer loses balance, has improved peripheral circulation and improved sensation in his lower legs and feet. His mood and energy have notably improved, and the patient reports an overall improvement of 80% in quality of life. He is no longer mentally confused from the pain medication.

Discussion

Chronic pain in the elderly presents with several confounding factors; diabetes mellitus and peripheral vascular disease being some of the existing co-morbidities to overlap the back pain or leg pain, especially in a patient with FBSS. FBSS is known to present with intractable pain in nearly 40% of patients undergoing multiple-level spinal fusion surgeries. SCS is known to produce at least 50% of pain reduction in this group of patients [2,12]. Some of these patients might be candidates for vertebral augmentation or vertebroplasty/kyphoplasty secondary to poor bone health and fractures of lumbar spine [13].

Considering the multiple surgeries, their lack of results regarding pain intensity and the patient's wish not to undergo any further surgeries in the future, we considered that the best option for this patient would be a minimally invasive, wireless SCS system.

The observed improvement in pain, both short- and medium-term, demonstrated that this patient could benefit from SCS despite his long history with chronic pain and complicated clinical history involving multiple pain sources and distributions. Improvement in walking seen post-implantation might be due to the improvement in sleep and the associated body recovery as well as the increased circulation that might have a positive impact in reducing muscle spasm, as well as the overall improvement in feeling and sensation in the lower limbs and feet.

The current insurance and health care system in the USA places neuromodulation at the end of the spectrum of treatment options, considering it a last resort after all conservative options have failed. With the new, less invasive and cost-effective

technology offered by Stimwave, patients are no longer asked to undergo traumatic, often less effective treatment options and/or surgery that might create permanent anatomical change before being offered neuromodulation and its potential pain relief.

This could also be a potential pathway to avoid having patients fall prey to the "opioid crisis" prevalent in the USA. Neuromodulation, which is now available with reduced risk of complications and improved recovery, could be offered before the patient is treated with opioids.

A lifetime cost comparison of the insurance requirements as to failed modalities (opioids, physical therapy, spinal surgery etc.) compared to a one-time neurostimulation implant and an updated risk assessment with the new, less invasive technology versus opioids and spinal surgery is warranted.

Conclusion

Wireless SCS was a successful option for a 67-year-old suffering debilitating low back and leg pain due to corrective back and neck surgery for scoliosis and vertebral collapse. Wireless SCS is an excellent treatment modality for such complicated cases and with the current, improved Nano-technology, perhaps the least traumatic and one of the most cost effective options available. This system is also capable of reaching difficult areas of pain distribution with versatile parameters for neuromodulation.

References

1. Aldrete JA (2006) Post laminectomy syndrome. In: ed. Pain Management 1st Edition. Waldman SD (Editor) Philadelphia: Saunders, USA. 818 pages.
2. Burchiel KJ, Anderson VC, Brown FD, Fessler RG, Friedman WA, et al. (1996) Prospective, multicenter study of spinal cord stimulation for relief of chronic back and extremity pain. *Spine (Phila Pa 1976)* 21: 2786-2794.
3. Pedrini L, Magnoni F (2007) Spinal cord stimulation for lower limb ischemic pain treatment. *Interact Cardiovasc Thorac Surg* 6: 495-500.
4. Wolter T (2014) Spinal cord stimulation for neuropathic pain: current perspectives. *J Pain Res* 7: 651-653.
5. Kumar K, Taylor RS, Jacques L, Eldabe S, Meglio M, et al. (2008) The effects of spinal cord stimulation in chronic pain are sustained: a 24-month follow-up of the prospective randomized controlled multicenter trial of the effectiveness of spinal cord stimulation. *Neurosurgery* 63: 762-770.
6. Kemler MA, De Vet HC, Barendse GA, Van Den Wildenberg FA, Van Kleef M (2008) Effect of spinal cord stimulation for chronic complex regional pain syndrome Type I: five-year final follow-up of patients in a randomized controlled trial. *J Neurosurg* 108: 292-298.
7. Holsheimer J, Khan YN, Raza SS, Khan E (2007) Effects of electrode positioning on perception threshold and paresthesia coverage in spinal cord stimulation. *Neuromodulation* 10: 34-41.

8. Cameron T (2004) Safety and efficacy of spinal cord stimulation for the treatment of chronic pain: a 20-year literature review. *J Neurosurg* 100: 254-267.
9. Perryman LT, Speck B, Weiner RL (2017) A Novel Wireless Minimally Invasive Neuromodulation Device for the Treatment of Chronic Intractable Occipital Neuralgia: Case Illustrations. *Journal of Neurology & Stroke* 6: 00213.
10. Weiner RL, Yeung A, Montes Garcia C, Tyler Perryman L, Speck B (2016) Treatment of FBSS Low Back Pain with a Novel Percutaneous DRG Wireless Stimulator: Pilot and Feasibility Study. *Pain Med* 17: 1911-1916.
11. Yearwood TL, Perryman LT (2015) Peripheral Neurostimulation with a Microsize Wireless Stimulator. *Prog Neurol Surg* 29: 168-191.
12. Baber Z, Erdek M (2016) Failed back surgery syndrome: current perspectives. *J Pain Res* 9: 979-987.
13. Kamalian S, Bordia R, Ortiz AO (2012) Post-vertebral augmentation back pain: evaluation and management. *AJNR Am J Neuroradiol* 33: 370-375.